


INTERNATIONAL JOURNAL OF UNANI AND INTEGRATIVE MEDICINE



E-ISSN: 2616-4558
P-ISSN: 2616-454X
IJUIM 2018; 2(2): 128-131
Received: 20-02-2018
Accepted: 21-03-2018

Mohammad Arif
Assistant Professor,
Dept. of Amraze Ain, Uzn,
Anf-o-Halaq (E.N.T.), Hakim
Syed Ziaul Hasan Govt. Unani
Medical College, Bhopal,
Madhya Pradesh, India

Athar Parvez Ansari
Research Officer (Unani),
Regional Research Institute of
Unani Medicine, Srinagar,
Jammu and Kashmir, India

Otomycosis treated with *Nufookh* (Insufflation) therapy in Unani system of medicine: A case report

Mohammad Arif and Athar Parvez Ansari

Abstract

Otomycosis is a fungal infection of external auditory canal characterized by itching, pain, sensation of ear blocking, impaired hearing and/ or ear discharge.

Two diagnosed cases of otomycosis were treated with *nufookh* (insufflation) therapy at E.N.T. OPD, HSZH Govt. Unani Medical College, Bhopal, Madhya Pradesh, India in 2017. Previously, the both patients were being treated with different allopathic antifungal ear drops and got temporary relief. The *nufookh* (insufflation) therapy of a compound Unani formulation, containing *Mur makki*, *Kundur*, *Suhaga*, *Rasout* and *Phitkari* was used for the treatment of both cases and showed significant result. It is recommended that this cost effective therapy with no reported adverse effect can be used for the treatment of uncomplicated cases of otomycosis.

Keywords: Otomycosis, *Nufookh* therapy, Insufflation, Unani Medicine

Introduction

Otomycosis is a fungal infection of the external auditory canal characterized by itching, pain, sensation of ear blocking, impaired hearing and/ or ear discharge ^[1]. Its prevalence is increases in warm and humid climates, particularly in rainy season ^[2]. The otomycosis is commonly caused by two groups of fungus such as *Aspergillus* and *Candida* spp. ^[3]. Several predisposing factors viz. absence of cerumen, humid and warm climate, bacterial otitis externa, corticosteroid therapy, swimming and local trauma due to sharp objects like sticks or hearing aids predisposes otomycosis ^[4].

The Unani classical literatures have been described the clinical features of otomycosis under *waja-ul-uzn* (otalgia) and *sailan-e-uzn* (otorrhoea). The renowned Unani physicians such as Ibn Sina (980-1037 AD), Razi (854-925 AD) and Ajmal khan (1868-1927 AD) have recommended the *nufookh* (insufflation) therapy with potent Unani drugs for the treatment of *selan-e-uzn* (otorrhoea) ^[5, 6, 7]. The *nufookh* (insufflation) therapy is a specific regimen in which the fine powder of single or compound drug is sprinkled into the ear canal through air pressure with the help of specially designed *nufookh* equipment ^[8].

Case presentation-1

A 35 year old female patient belongs to the middle class family was attended the outpatient department of E.N.T. at H.S.Z.H. Govt. Unani medical college, Bhopal in the month of August 2017 with the chief complaints of blockage, pain, heaviness and discharge from the right ear from one month. The patient had also history of using non-sterile oil in the ear. Before attending the OPD at HSZH Govt. Unani medical college, Bhopal, the patient has been treated with different allopathic antifungal ear drops named Clotrin AC and Mixbiotic ear drop and temporarily relieved from the sign and symptoms of otomycosis but recurrence of disease was found.

Examination of the patient

The *mizaj* (temperament) of the patient was assessed as per parameters described in a given proforma and it was found to be '*balghami*' (phlegmatic temperament).

The affected ear was examined by otoscope and the following signs were revealed:

- Blackish-white color mass filled in external auditory canal.
- External auditory canal was swollen, congested and narrow.
- Watery ear discharge present, may be due to use of ear drop.
- Tympanic membrane was examined after cleaning the canal and it was found that congested and intact.
- Tuning fork test shows conductive deafness.

Correspondence

Mohammad Arif
Assistant Professor,
Dept. of Amraze Ain, Uzn,
Anf-o-Halaq (E.N.T.), Hakim
Syed Ziaul Hasan Govt. Unani
Medical College, Bhopal,
Madhya Pradesh, India

The culture of ear discharge showed *Aspergillus niger*, a fungus and the growth of other organisms were absent.

Case presentation-2

A 42 year old male patient who was referred by a private practitioner to the outpatient department of E.N.T. at H.S.Z.H. Govt. Unani medical college, Bhopal in the month of September 2017 having severe earache, ear discharge, blockage and heaviness in the right ear from 3 weeks. The patient had not history of fever, common cold, URTI, diabetes mellitus, hypertension and other infectious or allergic diseases. He was a security guard by profession and performs his duty about 10 hours in a day. He belongs to the lower socioeconomic condition. He was treated with different allopathic oral and local antifungal drugs viz. clotrimazole and got temporary relief in pain but heaviness remained same.

Examination of the patient

The *mizaj* (temperament) of the patient was assessed as per parameters described in a given proforma and it was found that ‘*balghami*’ (phlegmatic temperament).

Otoscopic examination was done in the OPD. The detail of the examination is as under:

- (i) Whitish color fungus filled in external auditory canal.
- (ii) External auditory canal was swollen and narrow.
- (iii) Wet ear, may be due to use of ear drop.
- (iv) Tympanic membrane was examined after cleaning the canal. TM was congested and intact, no perforation seen.

The culture of ear discharge showed *Aspergillus niger*, a fungus and the growth of other organisms were absent.

Principle of treatment

The Unani principle of treatment is based on:

- i. *Izala-e-sabab* (remove the cause).
- ii. Keep ear open and dry.
- iii. Cleaning of external auditory canal.
- iv. Wash the ear canal with *sirka* (vinegar) and water into ratio 1:4 [5, 6, 9].
- v. *Nufookh* (insufflation) therapy by *musakkin* (analgesic), *muhallil* (resolvent), *mujaffif* (siccative) and *dafe Ta’ffun advia* (antiseptic drugs).
- vii. Use of *musakkin-e-alam advia* (potent analgesic) in case of severe pain.

Management of the patients

Both the patients were treated by *nufookh* (insufflation) therapy (Figure 2) only once and oral drug for 3 days. They were advised to keep the ear open and dry. The follow up was done after 3 days.

Nufookh (insufflation) therapy

The affected ear was cleaned by suction machine and washed with *sirka* (vinegar) and water (1:4) through syringing. After cleaning and drying of ear canal, the below mentioned formulation (Table1) in the form of fine powder was sprinkled in the external auditory canal through *nufookh* instrument (specially designed) (Figure 1) and extra powder sucked out by suction machine.



Fig 1: Nufookh (insufflation) instrument

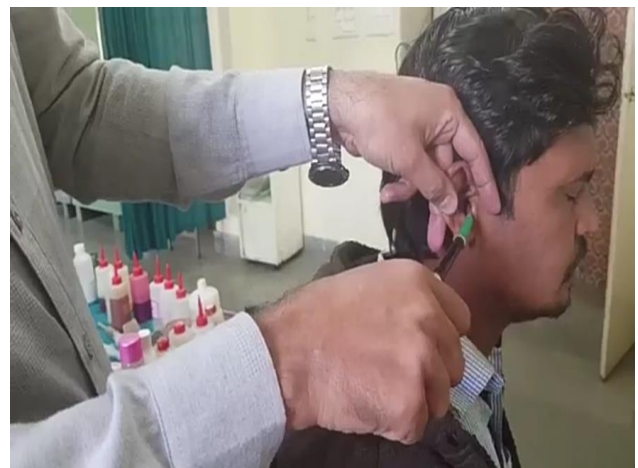

Fig 2: Nufookh (insufflation) given to the patient

Table 1: Formulation used for *nufookh* (insufflation) therapy

S. No.	Ingredients	Ratio
1.	<i>Mur makki (Balsamodendron myrrha Nees.)</i> [5, 6, 10, 11]	2 Part
2.	<i>Kundur (Boswellia serrata Roxb.)</i> [6, 7, 10-12]	2 Part
3.	<i>Suhaga (Borax)</i> [6]	2 Part
4.	<i>Rasot (Berberis aristata DC.)</i> [5, 10]	2 Part
5.	<i>Phitkari(Alum)</i> [5-7, 10, 11]	1 Part



Fig 3: Ingredients of formulation used as *nufookh* therapy

All the ingredients were finely powdered by using mortar and pestle followed by sieving through micro aperture sieve. The fine powder then filled into specially designed air tight container to use it for treatment purpose.

Drug used by oral route

Habb-e-Shifa, a compound Unani pharmacopoeial formulation (Table 2) was given to the both patients, one pill twice a day for 3 days to relieve severe pain.

Table 2: Ingredients of Habb-e-Shifa [13]

S. No.	Ingredients	Ratio
1.	<i>Joz-e-Masil (Datura stramonium Linn.)</i>	6 Part
2.	<i>Reward Chini (Rheum emodi Wall.exMeissn.)</i>	4 Part
3.	<i>Samag-e-Arabi (Acacia arabica Willd.var. indica Benth.)</i>	2 Part

Assessment of efficacy

The signs and symptoms of otomycosis were assessed according to Visual Analogue Scale (VAS) (Scale: 0 – 10).

Measures and Outcome

The earache, ear blockage, ear discharge and heaviness in

the affected ear of both patients were assessed according to Visual Analogue Scale (VAS) on 0 day and 3rd day and it was found that complete relief (Table 3). No adverse reactions of any drug used in this regimen were found during the treatment period.

Table 3: Assessment of otomycosis by using VAS (0-10 scale)

Sign/ Symptoms	VAS on 0 day	VAS on 3 rd day
Earache	10	0
Ear discharge	10	0
Ear blocking	08	0
Heaviness in the ear	06	0
Acute inflammatory changes (redness, swelling, heat)	08	0

Discussion

Otomycosis is a chronic superficial fungal infection affects the external auditory canal and the tympanic membrane. Unless manifested in the classical way, it is mostly misdiagnosed. It is usually associated with increased ear canal moisture, warmth and use of topical antibiotic ear drops, which may lead to depletion of protective cerumen layer, maceration of underlying skin, increase in ambient pH and modification of the microbial flora of external auditory canal. Many studies have been revealed that itching in the ear and earache are the major clinical feature of otomycosis [14-21]. However, in this case study, both patients had many clinical features viz; earache, heaviness, ear blockage and ear discharge.

According to Unani Medicine, such disease is commonly occurred in those who have excess *rutubat* (fluid) in the

body and their temperament indicates *balghami* (phlegmatic). Though, the Unani system of medicine is not exactly define otomycosis as such in Conventional medicine. But the clinical picture and management of otomycosis are dealt under the description of *waja-ul-uzn* (otalgia) and *selan-e-uzn* (otorrhoea). The Unani principle of treatment for such disease includes cleaning of external auditory canal (EAC), washing of EAC with diluted *sirka* (vinegar) solution and use of *musakkin* (analgesic), *muhallil* (resolvent), *mujaffif* (siccative) and *daf-e-ta'ffun advia* (antiseptic drugs) in the form of fine powder to sprinkle it in the EAC called as *nufookh* (insufflations) therapy. Cleaning with *sirka* (vinegar) and water solution helps to change the pH of canal causing reduction in fungus growth. The drugs includes *mur makki* (*Balsamodendron myrrha* Nees.), *kundur* (*Boswellia serrata* Roxb.), *suhaga* (Borax), *rasout*

(*Berberis aristata* DC.) and phitkari (Alum) have *musakkin* (analgesic), *muhallil* (resolvent), *mujaffif* (siccativ) and *daf-e-ta'ffun* (antiseptic) actions and are highly recommended to use them in the form of fine powder as *nufookh* (insufflation) therapy for the treatment of *selan-e-uzn* (otorrhoea) ¹⁶⁻¹⁰¹. The drugs used as *nufookh* therapy absorb the moisture of EAC and provide dry environment which is helpful to reduce the growth of fungus. It also acts as resolvent, anti-inflammatory and antiseptic. *Habb-e-Shifa* acts as potent analgesic to relieve severe pain.

Conclusion

Otomycosis is a common ear disease occurs in all age group. It can produce many serious complications including perforation of tympanic membrane, deafness, meningitis, encephalitis, facial palsy etc. In Conventional medicine, the treatment of otomycosis is based on antifungal ear drops, antifungal and analgesic oral drugs which are costliest; sometimes it requires long duration of treatment and also develop resistance in certain cases.

The management of otomycosis by *nufookh* (insufflation) therapy is convenient, cost effective, provide instance and complete relief with no reported adverse reaction in this case study.

Though, the Unani Medicine is very much popular for the treatment of several ailments include ear diseases, no reports are available on the efficacy of *nufookh* (insufflation) therapy in case of otomycosis. In this case study, the patient was completely relieved from the sign and symptoms of otomycosis after using the above mentioned formulation as *nufookh* (insufflation) therapy. Hence, it is recommended that otomycosis can be treated by using this cost effective formulation in the form of *nufookh* therapy.

Financial support and sponsorship: Nil.

Conflicts of interest: No conflict of interest.

References

1. Ho T, Vrabec JT, Yoo D. Otomycosis. Clinical features and treatment implications. *Otolaryngology - Head and neck surgery*. 2006; 135:787-791.
2. Chander J. Textbook of Medical Mycology. Ed. 3rd. Chandigarh. Mehta publishers, 2009, 418-419.
3. Vennewald I, Klemm E. Otomycosis- diagnosis and treatment. *Clin Dermatol*. 2010; 28(2):202-211.
4. Ozcan KM, Ozcan M, Karaarslan A, Karaarslan F. Otomycosis in Turkey: predisposing factors, etiology and therapy. *J Laryngol Otol*. 2003; 117:39-42.
5. Ibn Sina. *Alqanoon Fit Tib*. New Delhi. Idarah kitab al-Shifa, 2007, 206.
6. Razi Kitab, al-Havi. (Urdu translation by CCRUM). New Delhi. Dept. of AYUSH, Ministry of H & FW, Govt. of India, 1998: 14, 20, 21, 32, 34, 48, 3.
7. Khan A. Haziq. New Delhi. Idarah kitab al-Shifa. 2007; 124:128.
8. Kabiruddin. *Makhzan al-Mufradat*. Delhi. Idara kitabush shifa. 2014, 141, 227, 273, 330, 380.
9. Qamri AMH. *Ghina Muna*. (Urdu translation by CCRUM). New Delhi. Dept. of AYUSH, Ministry of H & FW. Govt. of India, 2008, 72-73.
10. Ahmad J, Tazkra-e-Jalil. (Urdu translation by CCRUM). New Delhi. Dept. of Ayush, Ministry of H & FW. Govt. of India, 2008, 119.

11. Majusi, Kamil al-Sana. (Urdu translation by Kanturi GH) Part. New Delhi. Idara Kitab al-Shifa. 2010: II(I):643.
12. Arzani A. *Tibb-e-Akbar*. New Delhi. Idarah kitab al-Shifa; YNM, 215.
13. Anonymous. *National Formulary of Unani Medicine, Part I*. New Delhi. Dept. of AYUSH, Ministry of Health & Family Welfare, Govt. of India, 2006, 31.
14. Satish HS, Viswanatha B, Manjuladevi M. A clinical study of otomycosis. *Journal of Dental and Medical Sciences*. 2013; 5(2):57-62.
15. Prasad SC, Kotigadde S, Shekhar M, Thada ND, Prabhu P, D' Souza T *et al*. Primary otomycosis in the Indian subcontinent: Predisposing factors, microbiology and classification. *International J of Microbiology*. 2014, 1-9.
16. Chapparbandi RB, Kazi FN, Ali K. Otomycosis: An overview in Hyderabad-Karnataka region. *J Evol of Med and Den Sci*. 2014; 3(46):11213-11216.
17. Haja AN, Shaik KM, Siva Subba Rao P. Mycology of otomycosis in a tertiary care teaching hospital. *J Res Med Den Sci*. 2015; 3(1):27-30.
18. Nandyal CB, Choudhari AS, Sajjan NB. A cross sectional study for clinico mycological Profile of otomycosis in North Karnataka. *Int J Med Health Sci*. 2015; 4(1):64-69.
19. Sarvan RR, Kikani KM, Mehta SJ, Joshi PJ. Clinico-mycological study of otomycosis. *Int J Biol Med Res*. 2012; 3(4):2469-2470.
20. Gokale SK, Suligavi SS, Baragundi M, Anushka D, Manjula R. Otomycosis: A clinico mycological Study. *Int J Med Health Sci*. 2013; 2(2):218-223.
21. Prasanna V, Hemlata Katiyar VM, Kannan I. Study of etiological factors, mycological profile and treatment outcome of otomycosis. *Int J of Medical Res*. 2014; 2(4):355-360.